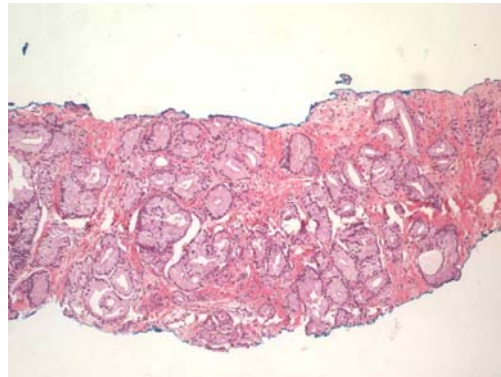


Test, Patient -- PL2009-002234Date of Birth:
08/31/1930Age:
78Gender:
MalePhysician:
**Test Physician MD
6620 Coyle Ave # 301
Carmichael, CA 95608
961-2514 voice**Facility:
Physician's OfficeCopies:
Test Physician**Finalized
01/14/2009****Received
01/13/2009****Collected
01/13/2009****DIAGNOSIS SUMMARY****Anatomic Pathology**

- A. Prostate Biopsy, Right Apex:
Adenocarcinoma, Gleason Score 6 (3+3)**
- B. Prostate Biopsy, Right Mid:
Adenocarcinoma, Gleason Score 6 (3+3)**
- C. Prostate Biopsy, Right Base:
Adenocarcinoma, Gleason Score 6 (3+3)**
- D. Prostate Biopsy, Left Apex:
Benign Fibromuscular Stroma**
- E. Prostate Biopsy, Left Mid:
Benign Fibromuscular Stroma**
- F. Prostate Biopsy, Left Base:
Benign Fibromuscular Stroma**

Anatomic Pathology**Comments**

- A. Adenocarcinoma involves one of the cores. The tumor is 8 mm in length. Overall about 90% of the length of the cores is involved. -- S. Bauer MD
- B. Adenocarcinoma involves 8 mm of the core. Overall about 100% of the length of the core is involved. -- S. Bauer MD
- C. Adenocarcinoma involves 11 mm of the core. Overall about 90% of the length of the core is involved. -- S. Bauer MD
- D. There is no glandular tissue in this sample. -- S. Bauer MD
- E. The findings are similar to those in specimen D. -- S. Bauer MD
- F. The findings are similar to those in specimen D. -- S. Bauer MD

Clinical Information


- A. Elevated PSA 15.33 ng/ml 11/08, DRE results-suspicious. -- K. Semerenko
- B. -- K. Semerenko
- C. -- K. Semerenko
- D. -- K. Semerenko

- E. -- K. Semerenko
- F. -- K. Semerenko

Gross Description

- A. Received in formalin labeled with the patient's name and "Right Apex Prostate" are two 0.2 to 1.4 cm cores of white tissue which are stained with bluing and submitted en toto in cassette A. -- K. Semerenko
- B. Received in formalin labeled with the patient's name and "Right Mid Prostate" is a 1.6 cm core of white tissue which is stained with bluing and submitted en toto in cassette B. -- K. Semerenko
- C. Received in formalin labeled with the patient's name and "Right Base Prostate" is a 1.7 cm core of white tissue which is stained with bluing and submitted en toto in cassette C. -- K. Semerenko
- D. Received in formalin labeled with the patient's name and "Left Apex Prostate" are two 0.3 to 1.2 cm cores of white tissue which are stained with bluing and submitted en toto in cassette D. -- K. Semerenko
- E. Received in formalin labeled with the patient's name and "Left Mid Prostate" are two 0.3 to 0.9 cm cores of white tissue which are stained with bluing and submitted en toto in cassette E. -- K. Semerenko
- F. Received in formalin labeled with the patient's name and "Left Base Prostate" is a 1.9 cm core of white tissue which is stained with bluing and submitted en toto in cassette F. -- K. Semerenko

Signature



Steve . Bauer, MD

Patient
Test, Patient
PL2009-002234

Path Logic
3637 Mission Ave
Bldg. A, Ste. 5
Carmichael, CA 95608 -

Peter Kolbeck, MD
Medical Director
916-863-1496
www.PathLogic.com