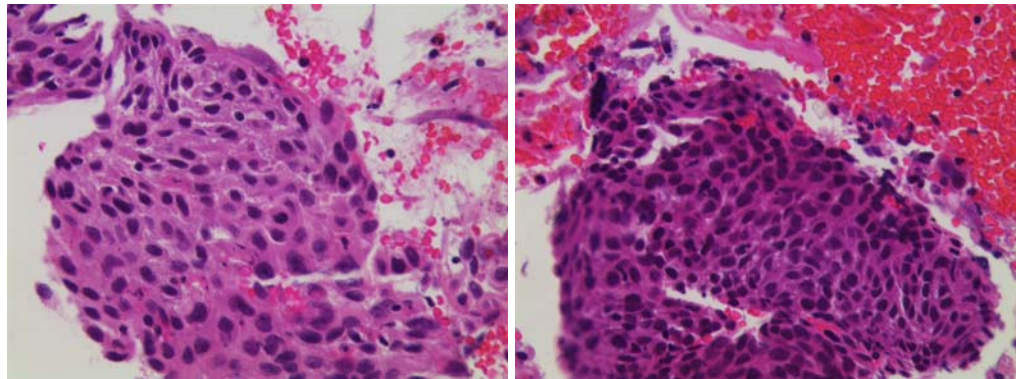


Test, Patient -- PL2009-002276Date of Birth:
06/30/1983Age:
25Gender:
FemalePhysician:
**Test Physician
2809 Olive Highway #370
Oroville, CA 95966
530-538-9410 voice
530-538-9411 fax**Facility:
Physician's Office

Copies:

Finalized
01/14/2009**Received**
01/13/2009**Collected**
01/13/2009**DIAGNOSIS SUMMARY****Anatomic Pathology**

- A. Cervix Spirabrush Biopsy:**
Benign Squamous and Endocervical Epithelium
- B. Cervix Spirabrush Biopsy:**
CIN II-III
- C. Cervix Spirabrush Biopsy:**
CIN III
- D. Cervix Spirabrush Biopsy:**
At Least CIN I
- E. Endocervix Curettage:**
CIN I

Anatomic Pathology**Comments**

- A. There is no koilocytosis or dysplasia. -- S. Shen MD
- B. There are areas of focal koilocytosis with cells with mildly enlarged nuclei and irregular nuclear membranes consistent with HPV effect. There is moderate basal hyperplasia and there are no abnormal mitoses. There is no endocervical glandular atypia (microscopic photograph, left) -- S. Shen MD
- C. There is marked basal immaturity. There are mitoses in the middle upper third of the epithelium (microscopic photograph, right). Atypical mitoses are not identified. Cytologic changes consistent with HPV effect are noted. -- S. Shen MD
- D. The dysplasia is seen in small fragmented tissue very focally. -- S. Shen MD
- E. There are multiple small fragments with koilocytosis. There is no significant basal hyperplasia, and there are no atypical mitoses. -- S. Shen MD

Clinical Information

- A. Hx of SIL or higher Pap/Bx. HPV infection; Hx/Rx. LMP 12/28/08. PrevPap 12/4/07, HISL. ASCUS/AGUS Pap/Bx w/in 2 years. -- H. Wong
- B. -- H. Wong
- C. -- H. Wong

D. -- H. Wong

E. -- H. Wong

Gross Description

- A. Received in formalin labeled with the patient's name and "A" is a Spirabrush. The material is scraped off of the brush, filtered and submitted en toto in a single cassette. -- H. Wong
- B. Received in formalin labeled with the patient's name and "B" is a Spirabrush. The material is scraped off of the brush, filtered and submitted en toto in a single cassette. -- H. Wong
- C. Received in formalin labeled with the patient's name and "C" is a Spirabrush. The material is scraped off of the brush, filtered and submitted en toto in a single cassette. -- H. Wong
- D. Received in formalin labeled with the patient's name and "D" is a Spirabrush. The material is scraped off of the brush, filtered and submitted en toto in a single cassette. -- H. Wong
- E. Received in formalin labeled with the patients name and "ECC" is a 1.0 x 1.0 x 0.1 cm aggregate of red-brown gelatinous material which is filtered and entirely submitted in one cassette. -- H. Wong

Signature



Shirley . Shen, MD

Patient
Test, Patient
PL2009-002276

Path Logic
3637 Mission Ave
Bldg. A, Ste. 5
Carmichael, CA 95608 -

Peter Kolbeck, MD
Medical Director
916-863-1496
www.PathLogic.com