

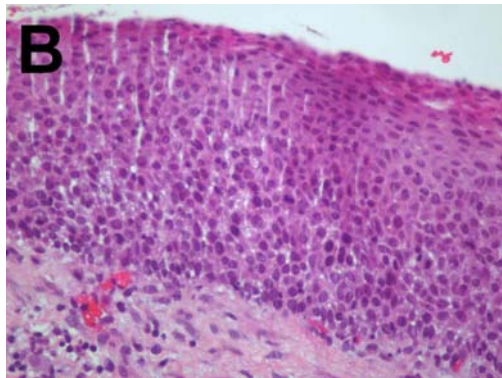
Murthy, Jane --Date of Birth:
01/01/1977Age:
35Gender:
FemalePhysician:
**Frederick Blair MD
2702 Low Court 2nd Floor-
OB/GYN
Fairfield, CA 94534
707-427-4900 voice
707-432-2800 fax**Facility:
**Sutter Fairfield Surgery
Center
2700 Low Court
Fairfield, CA 94534
707-432-2700 voice
707-432-2701 fax**

Copies:

Finalized
10/05/2012Received
10/03/2012Collected
10/02/2012**Diagnosis**

Anatomic Pathology

- A. Cervix Biopsy , Anterior 9-3 O'clock LEEP:
Atypical Squamous Metaplasia
- B. Cervix Biopsy , Posterior 3-9 O'clock/LEEP:
CIN III; Extension of CIN to the Inked Margin
- C. Endometrium Biopsy:
Atrophic Endometrium
- D. Cervix Biopsy , 10:00:
Benign Squamous Mucosa with Ulceration
- E. Endocervix Biopsy:
Benign Endocervical Epithelium

**Microscopic Description/Comments**

- A. No definite koilocytosis or CIN is identified. -- M. Argyres MD , 1200 B. Gale Wilson Blvd, Fairfield, CA
- B. There is marked basal immaturity. There are mitoses in the upper third of the epithelium. Atypical mitoses are present. Cytologic changes consistent with HPV effect are noted. The inked and cauterized margins appear to be involved. -- M. Argyres MD , 1200 B. Gale Wilson Blvd, Fairfield, CA
- C. There is no hyperplasia, neoplasm, polyp, or endometritis. -- M. Argyres MD , 1200 B. Gale Wilson Blvd, Fairfield, CA
- D. There is no koilocytosis or dysplasia. -- M. Argyres MD , 1200 B. Gale Wilson Blvd, Fairfield, CA

- E. There is no CIN or endocervical glandular atypia in the ECC. -- M. Argyres MD , 1200 B. Gale Wilson Blvd, Fairfield, CA

Clinical Information

- A. thru E.: Recurrent abnormal pap smears. [233.1]

Gross Description

- A. Received in formalin labeled "Murthy, Jane" and "cone biopsy cervix, anterior 9 o'clock to 3 o'clock" is a 1.2 x 0.6 x 0.5 cm annular portion of cervix with a pinpoint os. The mucosa is tan-white and grossly unremarkable. The endocervical margin is inked blue and the ectocervical margin is inked black. The specimen is serially sectioned in a clockwise fashion and entirely submitted one cassette labeled PL12-29885- A. Summary of sections: Five pieces. -- J. Welch
- B. Received in formalin labeled "Murthy, Jane" and "cervix biopsy posterior 9 o'clock to 3 o'clock" is a 0.7 x 0.5 x 0.3 cm rubbery soft tissue fragment consistent with cervix. The specimen is covered in blue dye. There is a possible edge of mucosa. The cauterized margins are inked black. The endocervical margin is not definitively identified. The specimen is serially sectioned and entirely submitted in one cassette labeled PL12-29885- B. Summary of sections: Three pieces. -- J. Welch
- C. Received in formalin labeled "Murthy, Jane" and "endometrial biopsy" is a 2 x 1 x 0.1 cm aggregate of tan- red friable soft tissue fragments admixed with blood clot and mucus. The contents are filtered and the specimen is entirely submitted in one cassette labeled PL12-29885- C. Summary of sections: Multiple pieces. -- J. Welch
- D. Received in formalin labeled "Murthy, Jane" and "cervix at 10 o'clock" is a 0.6 x 0.3 x 0.2 cm fragment of tan-white soft tissue consistent with cervix. The specimen is entirely submitted in one cassettes labeled PL12-29885- D. Summary of sections: One piece. -- J. Welch
- E. Received in formalin labeled "Murthy, Jane" and "endocervix biopsy" is a 2.3 x 1 x 0.1 cm aggregate of a tan- brown friable soft tissue fragments admixed with sparse blood clot and mucus. The contents are filtered and the specimen is entirely submitted in one cassette labeled PL 12-29885- E. Summary of sections: Multiple pieces. -- J. Welch

Signature



Michael Argyres , MD

Patient
Murthy, Jane

Path Logic
950 Riverside Pkwy
Suite 90
West Sacramento, CA 95605 -

Peter Kolbeck, MD
Medical Director
916-863-1496
www.PathLogic.com